

## Hypohidrotic Ectodermal Dysplasia: An Atypical Prosthetic Problem

Shital J Sonune M.D.S.

---

### Abstract

**Aim:** This clinical report of two cases describes the prosthodontic management of Hypohidrotic ectodermal dysplasia patient. **Background:** Hereditary ectodermal dysplasia is a specific syndrome characterized by congenital absence or deficient functions of two or more ectodermal structures and their accessory appendages manifested primarily by three clinical signs as hypotrichosis, hypodontia / anodontia (true) & hypohydrosis / anohydrosis.

The most frequently reported ectodermal dysplasia syndrome is X-linked hypohidrotic ectodermal dysplasia. It may not be apparent in the first year of life but it is usually diagnosed during infancy, after a bout of fever of unknown origin. Ectodermal dysplasia is commonly a difficult condition to manage with prosthodontics because of the typical oral deficiencies and the afflicted individuals are quite young when they are evaluated for treatment. It is important that these individuals receive dental treatment at an early age for physiologic & psychological reasons.

**Case description:** The treatment was focused on esthetic needs and oral functions & included fabrication of removable prosthesis for both the patient as inexpensive, reversible & conservative treatment approach. **Conclusion:** This clinical report demonstrates the importance of prosthodontic treatment for oral rehabilitation for ectodermal dysplasia patients. **Clinical significance:** The prosthodontic management of hypohidrotic ectodermal dysplasia patients with the condition of partial & complete absence of teeth by overdenture & complete denture prosthesis respectively, improved their physiological & psychological condition.

**Keywords:** Hypohidrotic ectodermal dysplasia; Anodontia; Prosthodontic treatment; Complete dentures; Overdenture.

---

### Introduction

Ectodermal dysplasia is a congenital syndrome characterized by developmental failure of two or more ectodermal structures. It had been suggested that the X-link trait is transmitted with the gene being carried by the female partner and manifested in the male partner.<sup>1</sup> The clinical manifestations of ectodermal dysplasia cause considerable social problems in children afflicted with the condition.

In spite of normal intellectual development, these children lack social & emotional proficiency due to abnormal facial appearance & absence of teeth. This problem starts with the school admission where children feel themselves different or rather indifferent from others. In such cases, an early helping hand with proper prosthodontic management creates a major impact on child's psychological drives.

This clinical report describes the characteristics & prosthodontic management of two cases of hypohidrotic ectodermal dysplasia in the same family.

### Case report I

A 21 year old male patient of hereditary ectodermal dysplasia presented with complaints of missing teeth and wanted replacement of the same for aesthetics and

---

**Author's Affiliation:** Assistant Professor, Department of Prosthodontics, Dr. D.Y. Patil Dental College & Hospital, Pimpri, Pune-18, M.S., India.

**Reprints Requests:** Dr. Shital J Sonune, M.D.S, Assistant Professor, Department of Prosthodontics, Dr. D.Y. Patil Dental College & Hospital, Pimpri, Pune-18, M.S., India.

E-mail: shitalsonune@yahoo.com

(Received on 27.07.2011, accepted on 24.09.2011)

mastication. Ten years ago (Figure 1) after fabrication of first set of maxillary overdenture & mandibular complete denture, within one & half years the patient started to feel some discomfort as a result of changes in dentoosseous structures of maxillary & mandibular arches. Hence the patient discontinued the use of prosthesis.

Apart from oral cavity, he did not have any major systemic complaint. The patient's father gave a history of absence of perspiration & irritation during the summer months.

The appearance of the father seemed to be normal. His hair was blond with normal texture & distribution. He showed no evidence of frontal bossing & bridge of his nose was not depressed. With the exception of his son & daughter, there was no history of this condition among other members of his family.

The patient showed concave soft tissue profile, protuberant lips (Figure 2) and few sparse hairs on scalp with sparse eyebrows and eyelashes. A depressed nasal bridge and frontal bossing were seen. The patient also had hyperkeratosis of the palms of the hands & soles of the feet.

Intra-oral features showed partial absence of teeth in maxillary arch & mandibular ridge was knife-edge type. The colour of the alveolar and oral mucosa was normal but xerostomia was evident. An orthopantomograph confirmed partial absence of teeth in maxillary arch & complete absence of teeth in mandibular arch (Figure 3).

Thus clinical and radiographical findings were suggestive of hypohidrotic ectodermal dysplasia with hypodontia in maxillary arch & anodontia in mandibular arch. In this case because of financial status and preference of selecting a reversible, non-invasive treatment modality, osseointegrated implants were not offered. Treatment planning was done by evaluating number & position of abutment and interarch space.

Two teeth in each quadrant are considered to be an ideal situation for overdenture as occlusal stress is distributed over a rectangular area.<sup>2</sup> To evaluate interarch space tentative jaw relation was taken & it was found that

posteriorly the space was sufficient but anteriorly interarch space was deficient (Figure 4). Hence, intentional root canal treatment of maxillary right & left canine was done & metal copings with chamfer margin were cemented. The cast metal copings with dome-shaped surface & a chamfer finish line (Figure 5) at the gingival margin provide support & stability to the overdenture.

Final impression was made in light body elastomeric impression material. On the final cast temporary record bases with occlusal rim were prepared & jaw relation was recorded. After teeth arrangement, during try-in jaw relation was verified with phonetic & esthetic acceptability by the patient. Processing of the denture was done in conventional manner and dentures were retrieved. Finishing and polishing of the denture was done. The patient adapted well to the dentures (Figure 6).

#### *Case report II*

The younger sister (12 years old) of the previously mentioned patient presented with the complaint of missing teeth and wanted replacement of the same for aesthetics and mastication. The patient's father gave history including the non-eruption of deciduous as well as permanent teeth. Because of negligence and lack of facilities in her hometown she had never visited any dentist earlier. Apart from oral cavity like her elder brother, she also did not have any major systemic complaint.

Intra-oral features showed under-developed edentulous upper and lower arches, lower ridge was knife-edge type and there was presence of marked bony undercut in maxillary anterior region (Figure 7). The colour of the alveolar and oral mucosa was normal with evident xerostomia. Extra-oral features were same as that of her elder brother.

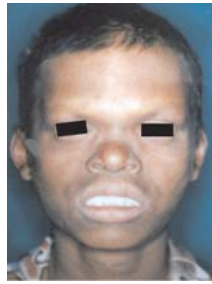True anodontia was confirmed with an orthopantomograph (Figure 8). Thus clinical & radiographical findings were suggestive of hypohidrotic ectodermal dysplasia with anodontia in maxillary & mandibular arches.

Primary impression was recorded with Type I impression compound. With green stick

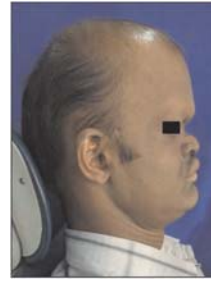compound, border molding was completed and final impression was made using light body elastomeric impression material. Jaw relation was recorded in a conventional manner & teeth of smaller size were selected. While teeth arrangement because of small jaw

size 1st premolars were eliminated. Try in was done. Processing of the dentures was done in conventional manner and dentures were retrieved. Finishing and polishing of the denture was done & dentures were delivered to the patient.

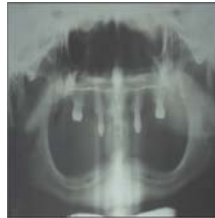**Figure 1 : The patient before treatment (ten years ago)**



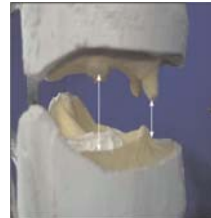**Figure 2 : The profile of patient before treatment shows concavity of face, protuberance of lips & frontal bossing**



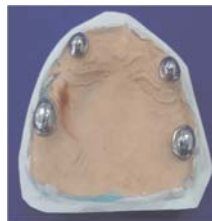**Figure 3: Orthopantomograph shows hypodontia in maxillary arch & anodontia in mandibular arch**



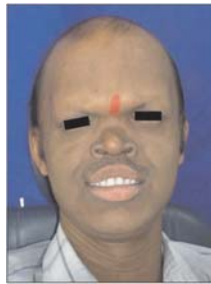**Figure 4: Tentative jaw relation**



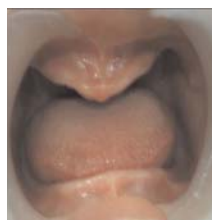
**Figure 5 : Dome-shaped cast metal copings with chamfer margin**



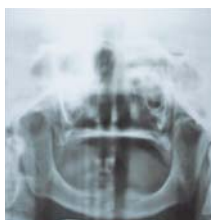**Figure 6 : Patient adapted well to the dentures**



**Figure 7 : Under developed edentulous upper and lower arches, lower ridge knife-edge type & presence of marked bony undercut in maxillary anterior region**



**Figure 8 : True anodontia confirmed with panoramic radiograph**



## Discussion

The ectoderm is one of the three germ layers of the embryo; it develops at, or around the 13<sup>th</sup> day in utero, which is earlier than the mesoderm & endoderm.<sup>3</sup> the ectodermal germ layer gives rise to those organs & structure that contact with outside world. They are the sensory epithelium of the ears, nose, eyes, skin, hair & nails; the pituitary, mammary & sweat glands; and the enamel of the teeth.

Ectodermal dysplasia is a pathogenic developmental defect, which at the embryologic level, affects the ectoderm & therefore the tissues and structures derived from it.<sup>4</sup> The most commonly encountered symptoms include deficient tears & saliva, poorly functioning mucus membrane, frequent respiratory tract infections, hearing & vision deficits, sensitivity to light & especially to heat.

Intraorally, hypodontia or anodontia of both primary as well as permanent dentition may be present. The alveolar processes are not well developed & protuberance of lips gives the characteristic senile facial appearance. The palatal arch is frequently high. Teeth if present appear to be conical in shape. Panoramic radiograph, biopsy of the palmer skin, pilocarpine iontophoresis together with skin sweat pore count, skin temperature measurements & dental evaluation form an important aspect of diagnosis of X-linked hereditary ectodermal dysplasia.<sup>5</sup>

Various treatment options are present to treat these patients prosthodontically.<sup>6</sup> In Implant Prosthodontics osseointegrated implants are a better option but dental & skeletal maturation must be taken into consideration to prevent future infraocclusion of the prosthesis.<sup>5</sup>

Fixed partial denture is seldom opted exclusively in the treatment of ectodermal dysplasia because many afflicted patients have a minimal number of teeth. Ectodermal dysplasia patients are often quite young when they are first treated & fixed partial denture with rigid connectors may interfere with jaw growth in young actively growing patients especially if the prosthesis crosses the midline.

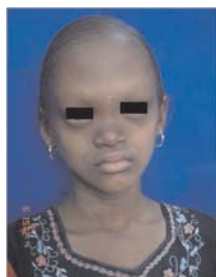Also larger pulp sizes & shorter crown heights may cause concern. Individual crown restoration & direct composite restorations have become the more desirable method of restoring normal morphology for hypoplastic teeth commonly found in ectodermal dysplasia patients.<sup>7</sup>

Anodontia or hypodontia is typical in individuals with this condition hence complete and removable partial dentures or overdentures are often parts of the treatment provided. Complete denture can provide an acceptable aesthetic & functional result. Underdevelopment of the edentulous alveolar ridges can comprise denture retention & stability. However vestibuloplasty & ridge augmentation may enhance the prosthodontic management of ectodermal dysplasia. When teeth are present for support, overdentures are desirable treatment option.

Hypohidrotic hereditary ectodermal dysplasia, though not a life threatening condition, can pose great impact on the physical, intellectual & psychological maturation of the patient. It can affect the normal living pattern not only of the patient but also the family. A sympathetic attitude and reassurance can help these patients to cope with their abnormal function and appearance and encourage them to comply with their normal social requirements.

In case I, for maxillary arch an overdenture is fabricated as the four maxillary teeth were in ideal position. The advantages of overdentures are (1) it greatly enhances stability which helps to eliminate ridge trauma (2) helps in retention of periodontal bone & (3) maintenance or periodontal proprioception.<sup>8</sup> Considering the age of this patient it would seem that presence of dentures did not significantly alter the facial bone growth. In case II, by placing complete denture prosthesis patient was subjected to improve in his speech, esthetics & function (Figure 9 & Figure 10). However because of growing jaws, the prosthodontic treatment was subjected to modification & reconstruction when necessary.

**Figure 9 : Frontal view of patient before treatment**



**Figure 10: The patient after prosthodontic rehabilitation**



The aims and objectives of the treatment modalities provided to these particular patients are improvements in the aesthetics, phonetics, function and mastication, which will improve the tone of the facial and masticatory muscles.

### Conclusion

Hereditary ectodermal dysplasia is only a group of syndromes that also constitute prosthodontic problems. The characteristic features associated with ectodermal dysplasia often result in afflicted individuals having an abnormal facial appearance due to partial or complete absence of teeth. Ectodermal dysplastic children should be referred for prosthodontic consultation at an early stage as normal social and psychological development of young ectodermal dysplasia patients dictates the way they look & feel. Therefore, dentate appearance in these patients is extremely important because it can affect their self-esteem.

### Acknowledgment

I am deeply thankful to Dr. Sachin Sarode and Dr. Gargi Sarode for all constructive suggestions and sincere, untiring efforts in proofreading.

### References

1. Clarke A. Hypohidrotic ectodermal dysplasia. *J Med Genet* 1987; 24:659-63.
2. Preiskel HW. Precision attachments in prosthodontics: overdentures and telescopic prostheses. *Quintessence Int* 1985; 2.
3. Ten Cate AR. *Development structures and functions*. In: Ten Cate AR (Ed). *Oral Histology*, Ed 4. St Louis: Mosby, 1994; 3-7.
4. Freire-Maia N. Ectodermal dysplasia revisited. *Acta Genet Med Gemellol Roma* 1977; 26: 121-5.
5. Itthagarum A, King NG. Ectodermal dysplasia: a review and case report. *Quintessence Int* 1997; 28: 595-602.
6. Pigno MA, Blackman RB, Cronin RJ Jr., Cavazos E. Prosthodontic management of ectodermal dysplasia: a review of the literature. *J Prosthet Dent* 1996; 76: 541-5.
7. Lo Muzio L, Bucci P, Carile F, Riccitiello F, Scotti C, Coccia E, Rappelli G. Prosthetic rehabilitation of a child affected from anhydrotic ectodermal dysplasia: a case report. *J Contemp Dent Pract* 2005; 6: 120-126.
8. Nortje CJ, Farman AG, Thomas CJ, Watermeyer GJJ. X-linked Hypohydrotic ectodermal dysplasia-an unusual prosthetic problem. *J Prosthet Dent* 1978; 40: 137-142.

**BOOKS FOR SALE****CHILD INTELLIGENCE****By Dr. Rajesh Shukla**

ISBN: 81-901846-1-X, Pb, vi+141 Pages

Price: Rs.150/-, US\$50/-

Published by **World Informations Syndicate**

This century will be the century of the brain. Intelligence will define success of individuals; it remains the main ingredient of success. Developed and used properly, intelligence of an individual takes him to greater heights. Ask yourself, is your child intelligent! If yes, is he or she utilizing the capacity as well as he can? I believe majority of people, up to 80% may not be using their brain to best potential. Once a substantial part of life has passed, effective use of this human faculty cannot take one very far. So, parents need to know how does their child grow and how he becomes intelligent in due course of time. As the pressure for intelligence increases, the child is asked to perform in different aspects of life equally well. At times, it may be counter-productive. Facts about various facets of intelligence are given here. Other topics like emotional intelligence, delayed development, retardation, vaccines, advice to parents and attitude have also been discussed in a nutshell. The aim of this book is to help the child reach the best intellectual capacity. I think if the book turns even one individual into a user of his best intelligence potential, it is a success.

**PEDIATRICS COMPANION****By Dr. Rajesh Shukla**

ISBN: 81-901846-0-1, Hb, VIII+392 Pages

Price: Rs.250/-, US\$50

Published by **World Informations Syndicate**

This book has been addressed to young doctors who take care of children, such as postgraduate students, junior doctors working in various capacities in Pediatrics and private practitioners. Standard Pediatric practices as well as diseases have been described in a nutshell. List of causes, differential diagnosis and tips for examination have been given to help examination-going students revise it quickly. Parent guidance techniques, vaccination and food have been included for private practitioners and family physicians that see a large child population in our country. Parents can have some understanding of how the doctors will try to manage a particular condition in a child systematically. A list of commonly used pediatric drugs and dosage is also given. Some views on controversies in Pediatrics have also been included. Few important techniques have been described which include procedures like endotracheal intubations, collecting blood samples and ventilation. I hope this book helps young doctors serve children better.

**Order from**

Red Flower Publication Pvt. Ltd.

41/48, DSIDC, Pocket-II, Mayur Vihar, Phase-I

P.O. Box No. 9108, Delhi - 110 091 (India)

Tel: 91-11-65270068, 22754205, Fax: 91-11-22754205

E-mail: redflowerpppl@gmail.com, redflowerpppl@vsnl.net